Ashman-Gouaux Phenomenon

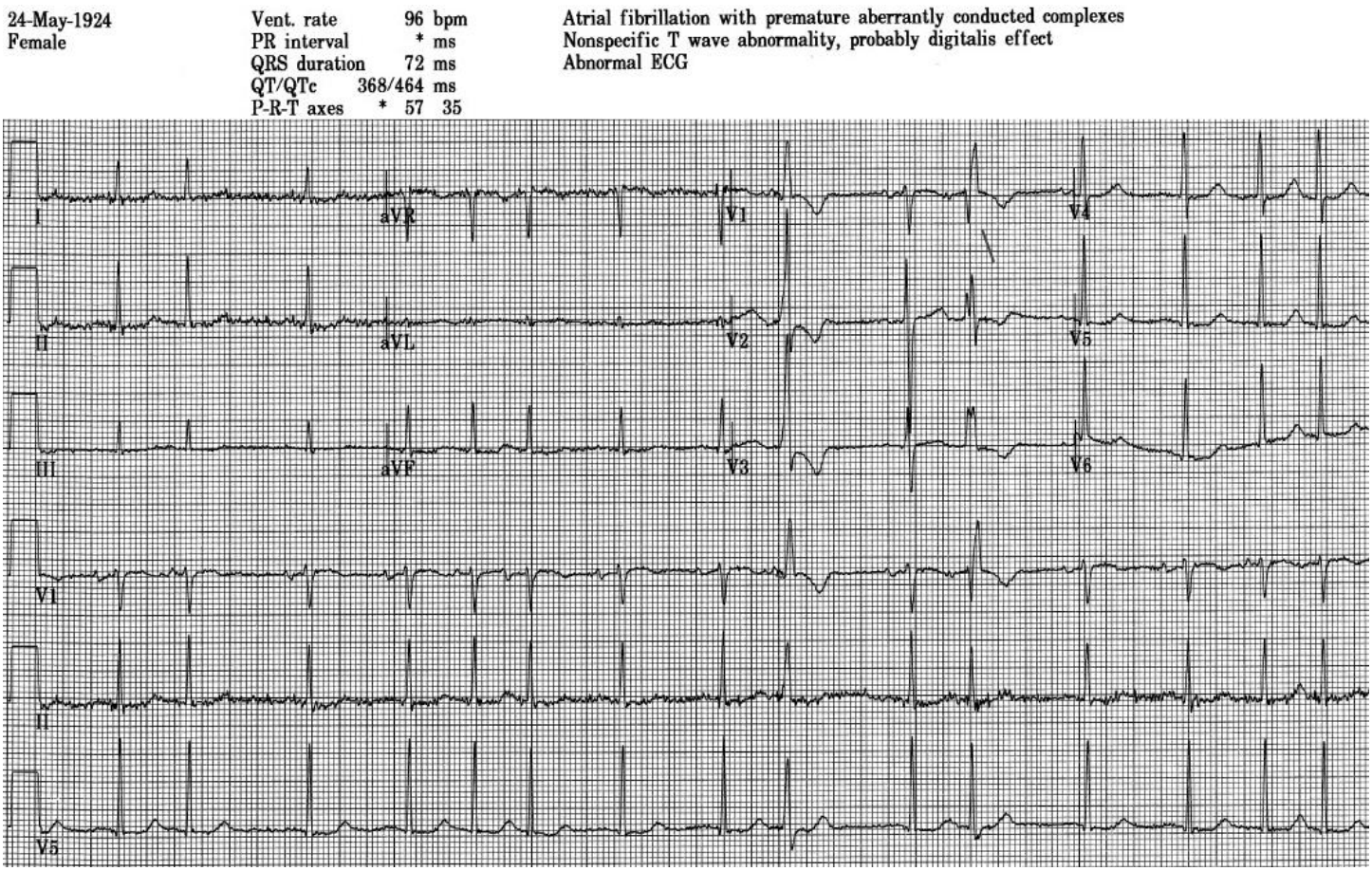

Figure 1

What we commonly think of today as the "Ashman phenomenon" is actually the "Ashman-Gouaux phenomenon" because it was discovered by *two* researchers working together – not just *one!* Unfortunately, a name that was very difficult for non-francophones to pronounce was sadly misplaced in history. I always try to give Dr. Gouaux his recognition whenever I can. (By the way, it's pronounced "Goo-oh" – two syllables.)

The Ashman-Gouaux phenomenon was first discovered while the two researchers were studying *atrial fibrillation*. However, it can also appear during sinus rhythm. Actually, its appearance during atrial fibrillation can be somewhat problematic because the same conditions that predispose to the Ashman-Gouaux phenomenon can also result in reentrant ventricular ectopy – something entirely different. In spite of the machine interpretation, this ECG does *not* demonstrate atrial fibrillation which is made quite clear by looking at the Lead V1 rhythm strip. Most likely, this rhythm represents a *wandering atrial pacemaker* which also results in a very irregular rhythm. ***Never trust the ECG machine's interpretation!***

24-May-1924
Female

Vent. rate 96 bpm
PR interval * ms
QRS duration 72 ms
QT/QTc 368/464 ms
P-R-T axes * 57 35

Atrial fibrillation with premature aberrantly conducted complexes
Nonspecific T wave abnormality, probably digitalis effect
Abnormal ECG

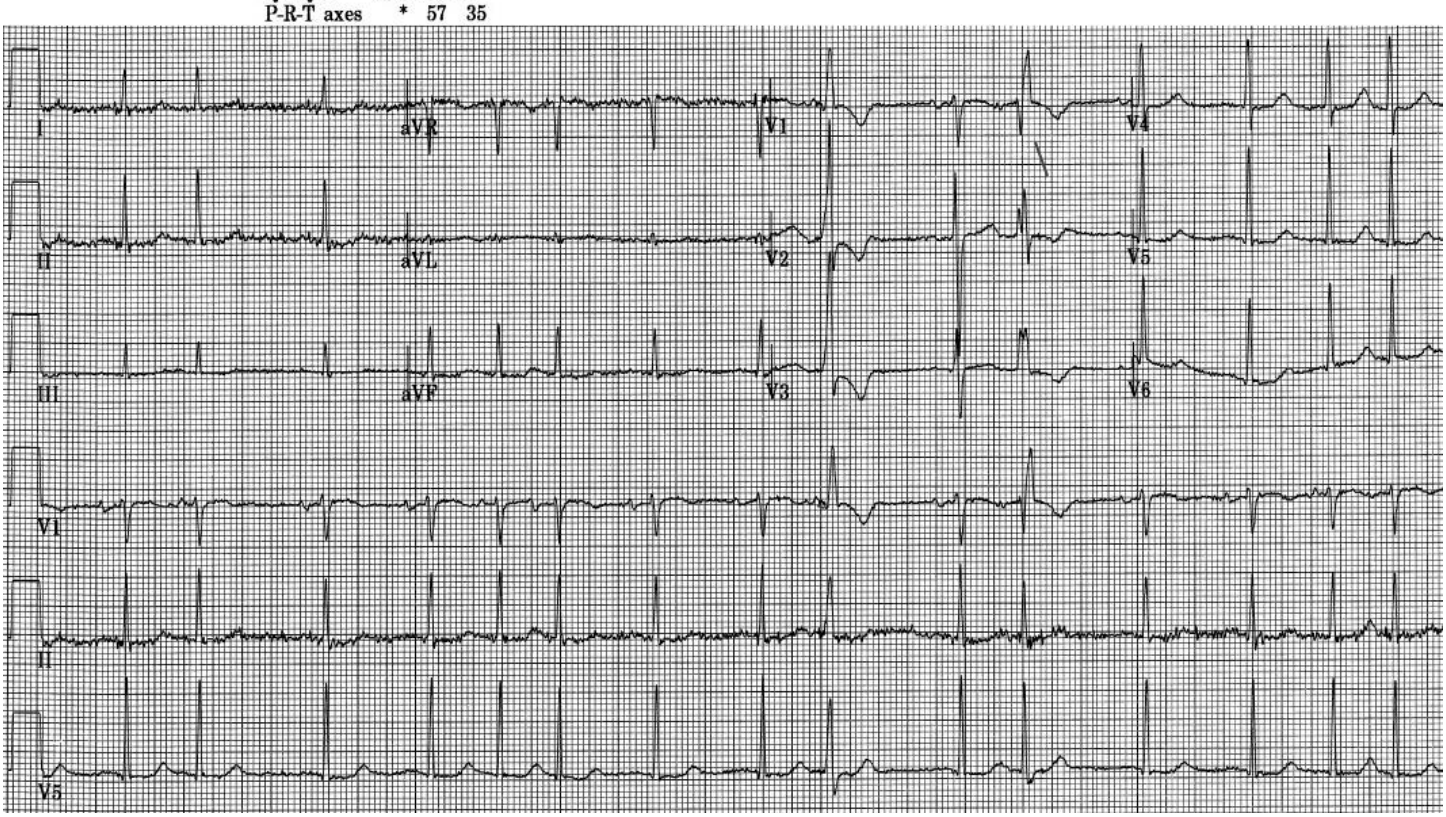

Figure 1 (repeated)

There are two examples of the Ashman-Gouaux phenomenon on this 12-lead ECG. In this case, they appear in succession. One of the examples (the first one) is suggestive of underlying ischemic heart disease. Perhaps more on that in another post.

The set-up for the Ashman-Gouaux phenomenon is the appearance of a *long* R-R interval followed by a *short* R-R interval. *The QRS complex that ends the short R-R interval is conducted aberrantly*. This aberrant conduction is usually in the form of a right bundle branch block (RBBB) but, rarely, it may manifest as a left bundle branch block (LBBB).

Look at the Lead V1 rhythm strip (in the middle of the ECG).

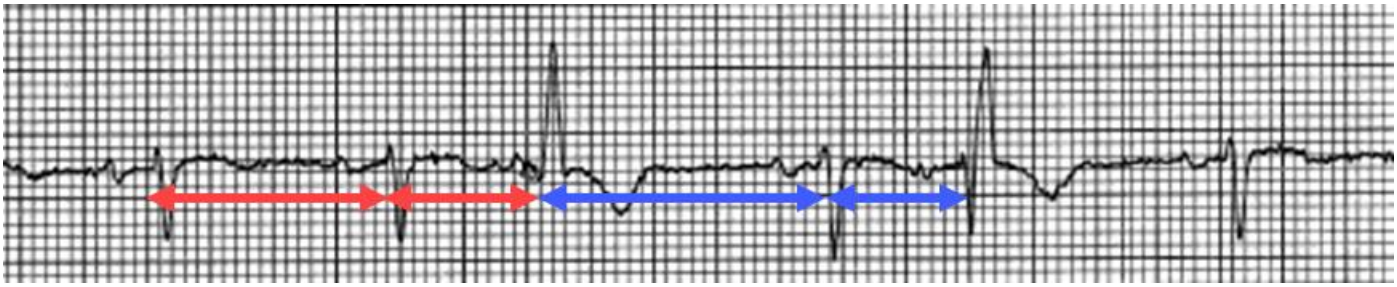

Figure 2

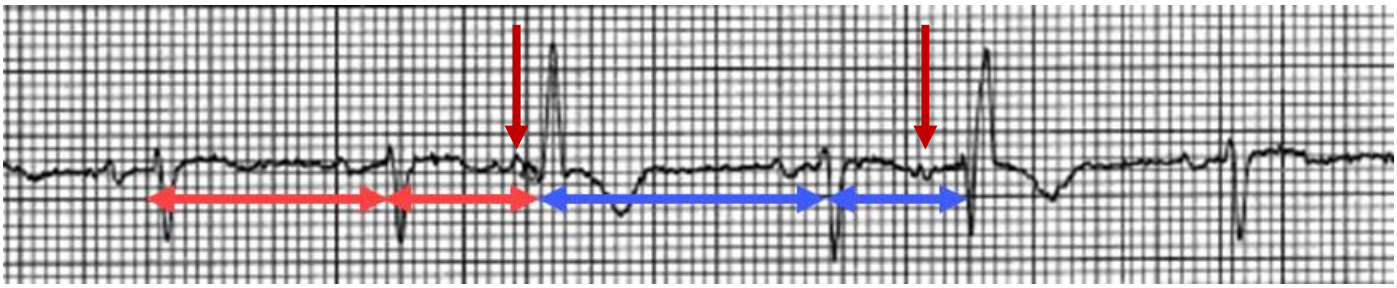

Figure 2 (repeated)

In the first example (red) of the Ashman-Gouaux phenomenon, we see a long R-R interval followed by an aberrantly conducted beat that ends a short R-R interval. In the second example (blue), we also see a long R-R interval followed by a short R-R interval that is terminated with an aberrantly conducted QRS. In this case, the long R-R interval begins with the previous aberrantly-conducted beat. That's OK… *there's no rule against that*. It's still a QRS.

Please note that the intervals we are measuring here are R-R intervals and *not* P-P intervals. That's because we are going to be concerned primarily with what is happening in the *ventricles* – *not* the atria. Don't get confused! When we measure for compensatory and non-compensatory pauses, we are looking for any effect the ectopic beat may have had on the *sinus node*; therefore, we measure from P wave to P wave. As you are about to discover, the Ashman-Gouaux phenomenon is concerned with the refractory periods of the bundle branches and their ramifications, i.e., *ventricular* issues.

How do we know that the two aberrantly-conducted beats are not actually ventricular ectopics? (Remember: an aberrantly-conducted QRS *looks* like an ectopic beat, but it's actually a *bundle branch block.*) First, both are preceded by P waves (do I need to go any further?). Second, there is no compensatory pause, which would be problematic anyway since the atrial rhythm is so irregular.

So, the Ashman-Gouaux phenomenon tells us that when there is a long R-R interval followed by a short R-R interval, the QRS ending the short R-R interval will be conducted aberrantly… *right?* At the most BASIC…ELEMENTARY…REMEDIAL level of ECG knowledge, I would say, "Yes." But that really was *not* their discovery that was so ground-breaking!

What we learned from Drs. Ashman and Gouaux was that ***each R-R interval determines the refractory period for the following R-R interval***. So, with reference to the Ashman-Gouaux phenomenon, that long R-R interval has created a long refractory period for the following R-R interval. Normally, that's not a problem because sinus rhythm is usually regular enough to keep all the ventricular depolarizations outside that long refractory period and conduction proceeds with no aberrancy. But should an impulse arrive in the ventricles a little *too soon*…

Figure 1 (repeated)

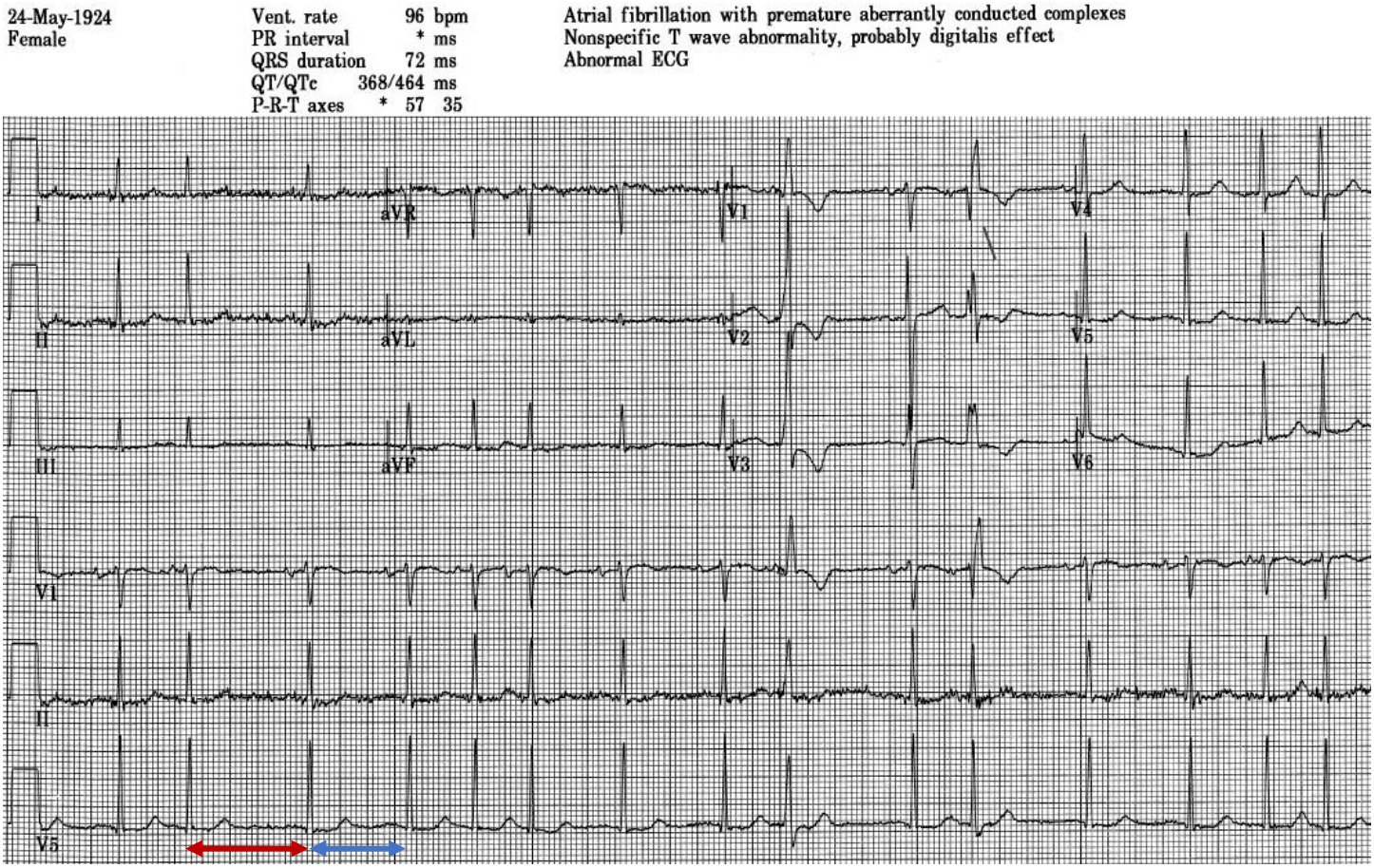

…conduction through the ventricular conduction system will be aberrant. Once again, if you look at the two aberrantly conducted beats in Lead V1, you will notice that they appear different. The first is basically a monophasic R wave (*atypical* RBBB) while the second appears to be a *classic* RBBB. There is obviously a difference in the amount of aberrancy between the two impulses. This is usually due to the relative lengths of the two (long and short) R-R intervals.

If you look at the beginning of the three rhythm strips (V1, II, V5) at the bottom of the ECG, you will see a long R-R interval (dark red) followed by a shorter R-R interval (blue) – *but there is no aberrant conduction*. In this case, had the long R-R interval been *longer* or the short R-R interval been *shorter*, we may have seen an aberrantly-conducted QRS terminating the short R-R interval.

To summarize…

1. **The Ashman-Gouaux phenomenon occurs when a long R-R interval is followed by a short R-R interval that is terminated by an aberrantly-conducted QRS (usually RBBB, rarely LBBB).**
2. **What the Ashman-Gouaux phenomenon *means* is that each R-R interval sets the refractory period of the ventricular conduction system for the *next* R-R interval.**

So, the real importance of the Ashman-Gouaux phenomenon lies not so much in its *recognition*, but rather in *understanding* what it means!

I hope you enjoyed this post. Please join us next year (2022) here in Houston, Texas for the ***Masterclass in Advanced Electrocardiography***, and the ***Masterclass in Advanced Dysrhythmias***.

Here's wishing all of you a safe, healthy, and prosperous New Year!



MEDICUS OF HOUSTON

BE A PARTICIPANT... NOT JUST AN AUDIENCE!

https://medicusofhouston.com