Things to Note on a NORMAL 12-Lead ECG for More Advanced ECG "Nerds"

11-Dec-2011 19:33:48

23-Sep-1954
Female Hispanic

Vent. rate	75 bpm
PR interval	132 ms
QRS duration	92 ms
QT/QTc	418/466 ms
P-R-T axes	12 1 25

Normal sinus rhythm
Normal ECG

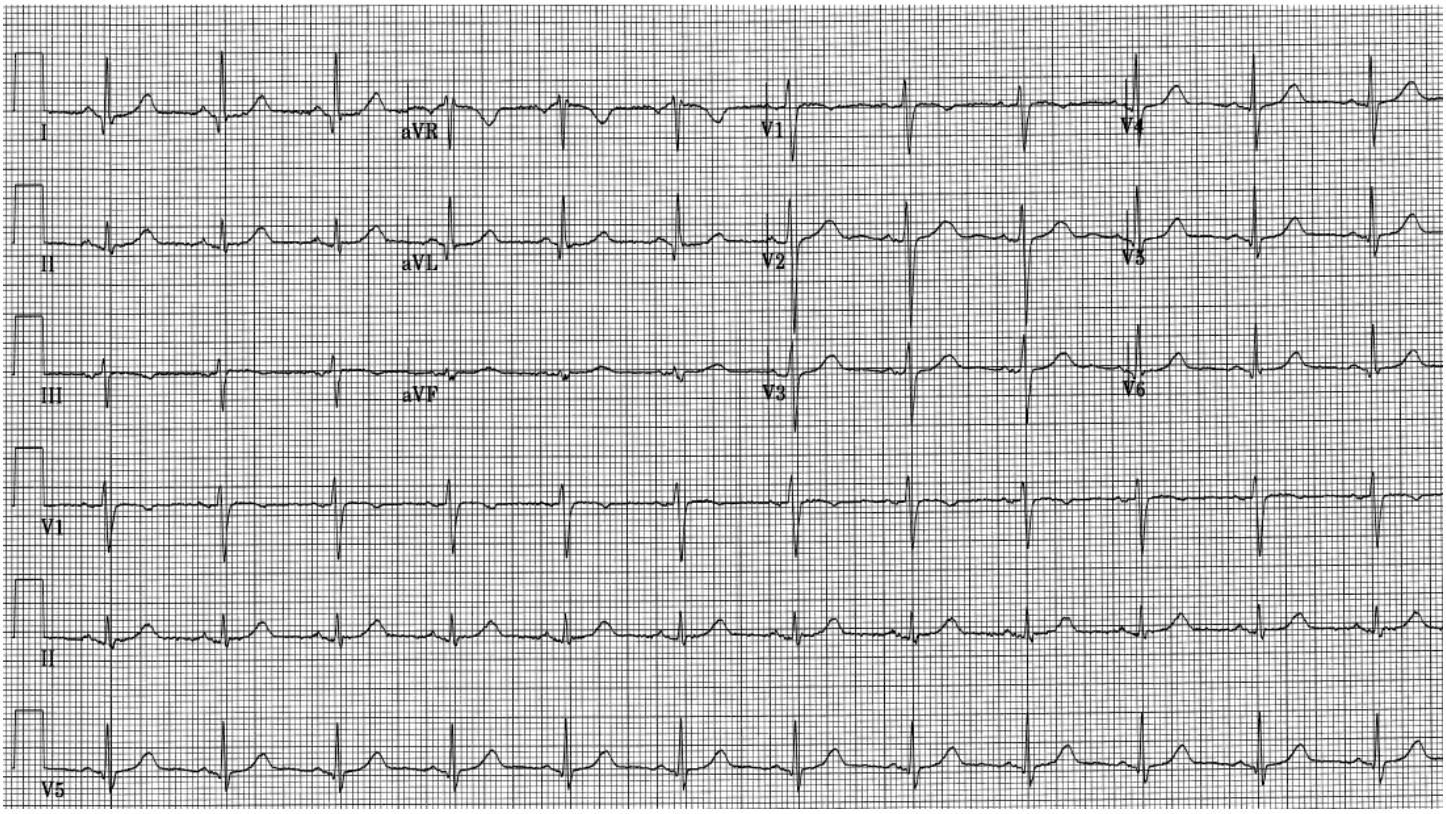

I presented this ECG a few days ago with some thoughts and perspectives for the beginning to intermediate ECG learners. Today, I want to discuss some things more at the advanced level. Of course, EVERYONE is invited to join in!

Again, this really is a normal ECG – no tricks.

I discussed the appearance and implications of septal q waves in the last post. For this post, I want to move from the beginning of the QRS to the end of the QRS. Let's take a close look at the endings of the QRS intervals. They are officially called QRS *intervals* – not QRS *complexes,* though most people (myself included) usually use the term *complex*.

Let's look at Leads I, aVL and V6. As you may or may not know already, you should always compare the morphology of the QRS in Lead I to that in V6. Their axes are somewhat aligned, and their positive poles are essentially located in the same place, so those two leads should always look very similar. They don't have to look *exactly* the same, but they should have the same polarity and a similar R/S ratio. If they don't, think in

terms of a lead wire switch, a divisional block in the left ventricle (LAFB, LPFB) or the recording of a right-sided ECG lead (such as V4R) or a posterior lead (V9) that wasn't noted on the ECG paper.

Each of those three leads – I, aVL, V6 – ends with a very small s wave. That indicates that at the very end of depolarization, the impulse turned around and began traveling to the right – hence the terminal negative deflections in the left-sided leads. To confirm this, we would like to see a right-sided lead. No right-sided ECG (V3R, V4R etc.) was done, but the standard 12-lead ECG always has a right-sided lead that is even MORE right-sided than V6R: Lead aVR. Don't forget that Lead aVR is the quintessential right-sided lead and will occasionally bear a close resemblance to Lead V1 – especially in the presence of RBBB.

When we look at Lead aVR, we see that it ends with a very tiny r′ wave. That confirms a terminal vector pointing to the right. Most young people end the depolarization of the heart in the area we call the right ventricular outflow tract. In those subjects, the tiny s wave at the end of the QRS in the left-sided leads and the tiny r′ wave in aVR are a bit larger – but not too much larger. Because the terminal vector points toward a part of the right ventricle we call (more specifically) the *crista interventricularis*, we call this pattern a *cristal pattern*. Sounds like we're talking about wedding gifts, but we aren't! This cristal is spelled with an "i."

As we age, the termination of the ventricular depolarization vector points more superiorly, to the left and somewhat posteriorly. The cristal pattern disappears. This woman is probably somewhere in between.

So why do we need to know this? Because sometimes those little s waves and r′ waves are a bit larger than normal and are often misinterpreted as RBBB or incomplete RBBB.

Next, did you notice the U waves in Lead V2. They aren't well seen in any of the other leads. I just want to remind you that there are absolutely no other deflections between QRS intervals other than the T wave, the U wave and the P wave. It's important to remember this because just as we can see inverted T waves (look in V1) and inverted P waves (look in Lead III) you can see inverted U waves which are highly indicative of proximal occlusive disease of the left anterior descending coronary artery (LAD). While the inverted T wave and the inverted P wave are very obvious, the inverted U wave is *not*. We often forget that the only deviation of the baseline between the end of the T wave and the onset of the P wave will be a U wave – and that includes *any deviation downward* which is *highly* abnormal and pathological!

For the last topic, we turn to the horizontal plane – the precordial leads V1 – V6. Just as we have a mean QRS axis in the frontal plane, we have a mean QRS axis in the horizontal plane – except we don't call it a mean axis. We refer to it as the QRS ***rotation***. And we don't think of it so much in specific degrees like in the frontal plane. We're more concerned with *where the transition from rS morphology to RS occurs*. REMEMBER: ***transition occurs where the R/S ratio becomes 1.0, i.e. the R wave and the S wave are exactly equal***. The point at which the QRS develops an Rs morphology is NOT the transition.

But I want to focus on the so-called "r wave progression." When people see a "poor r wave progression" they too often immediately diagnose an "old anteroseptal infarction." Chest electrode malpositioning, advanced emphysema and anterior fascicular block are much more common causes. Let's look at the ECG above. When you look at the precordial leads, focus on V1 – V3 for now. Do you notice anything that strikes you as abnormal or at least, unexpected?

The r wave in V2 is larger than the r wave in V3. It should be just the opposite, shouldn't it? Shouldn't the r waves get progressively larger until V5, with the R wave in V6 slightly smaller than in V5?

No, not really. The reason is that the term "r wave progression" is wrong! It's a misnomer. What actually progresses is **the R/S ratio** – *not necessarily the physical size of the r waves alone*. As the R/S ratio progresses,

the ratio becomes greater and greater. Eventually – at some point – the height of the R wave equals the depth of the S wave. Sometimes you can see this in one of the leads which will have an equiphasic QRS, but more often it occurs between recorded leads. The R/S ratio increases to the point that it is much greater than 1.0, sometimes many times that amount! In the ECG above, although the r wave in lead V2 is larger than that in V3, the R/S ratio in V2 is 0.46 while the R/S ratio in V3 is 0.56. Thus, there IS progression of the R/S ratio – as predicted and as expected!

Thank you for your time and attention.

Check out the **Medicus of Houston** website for more information on my classes.

Come join us and be a PARTICIPANT… never just an audience!